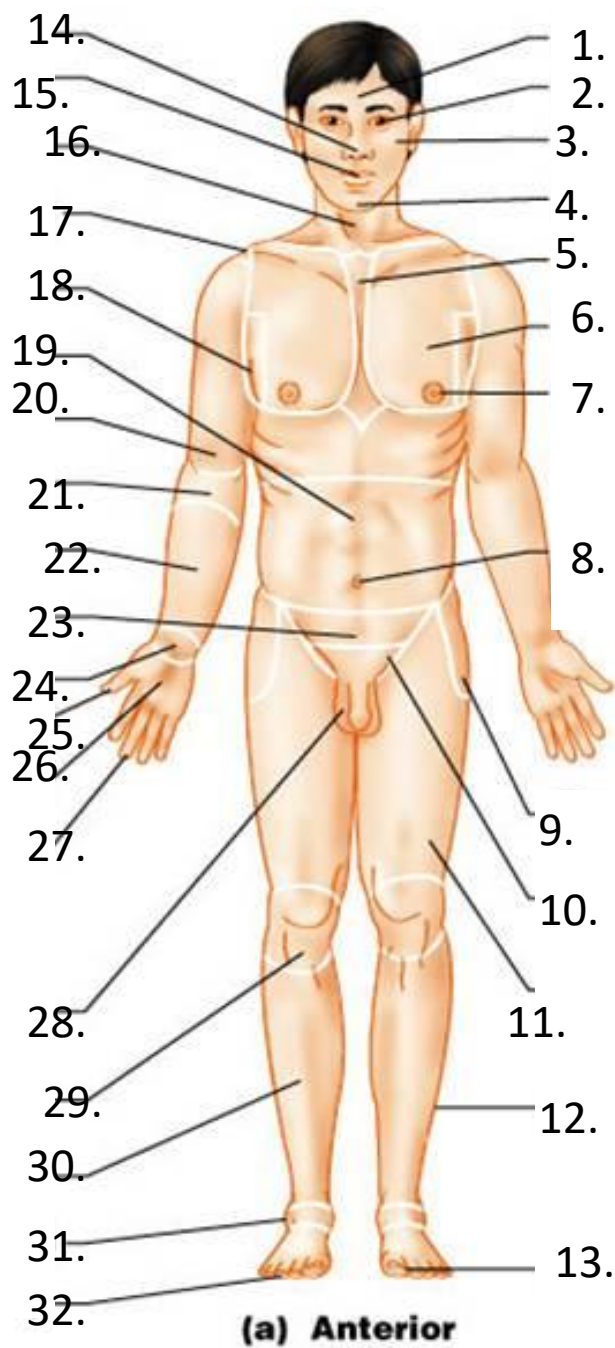
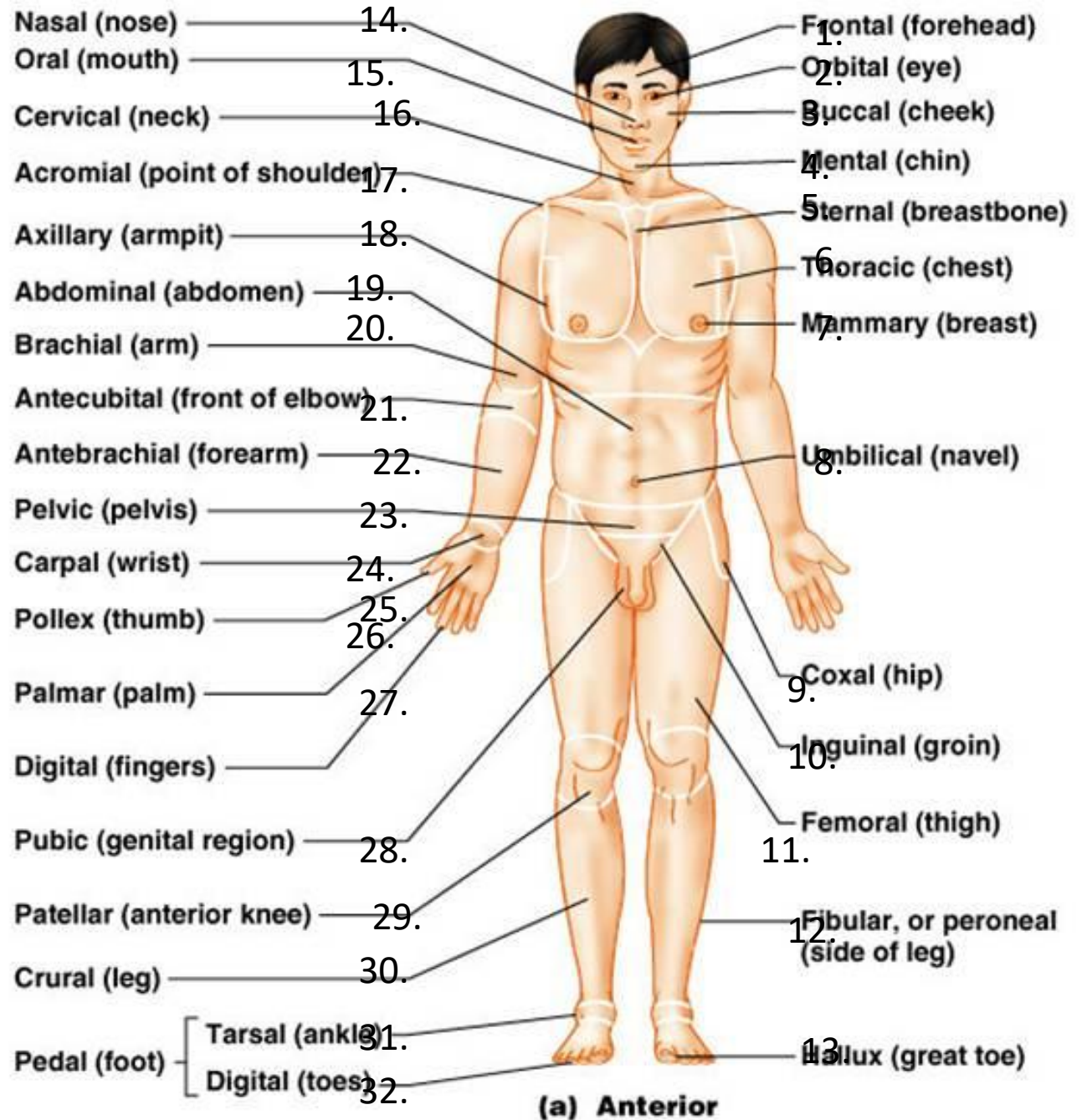


Anatomy Review

Regions

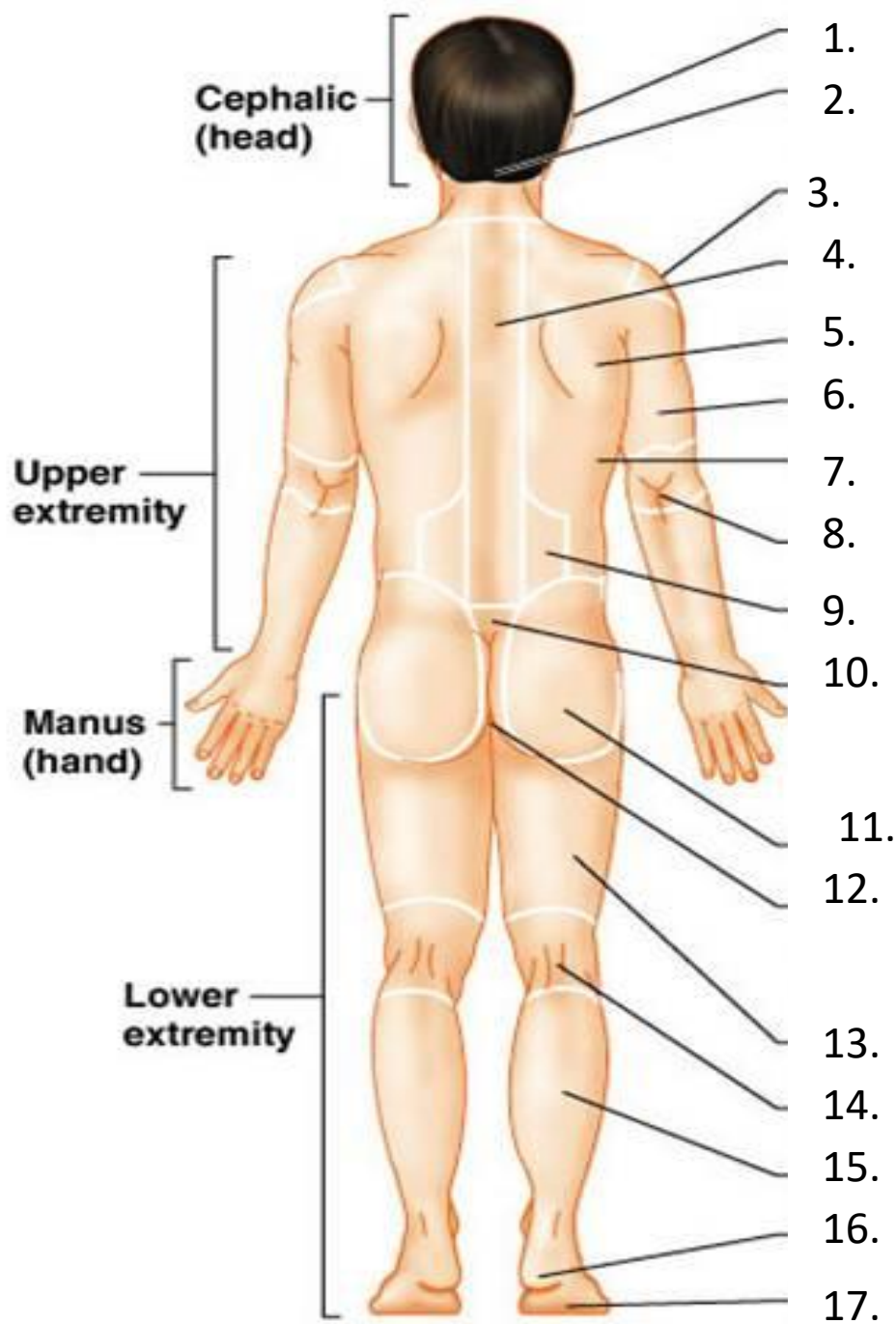


(a) Anterior



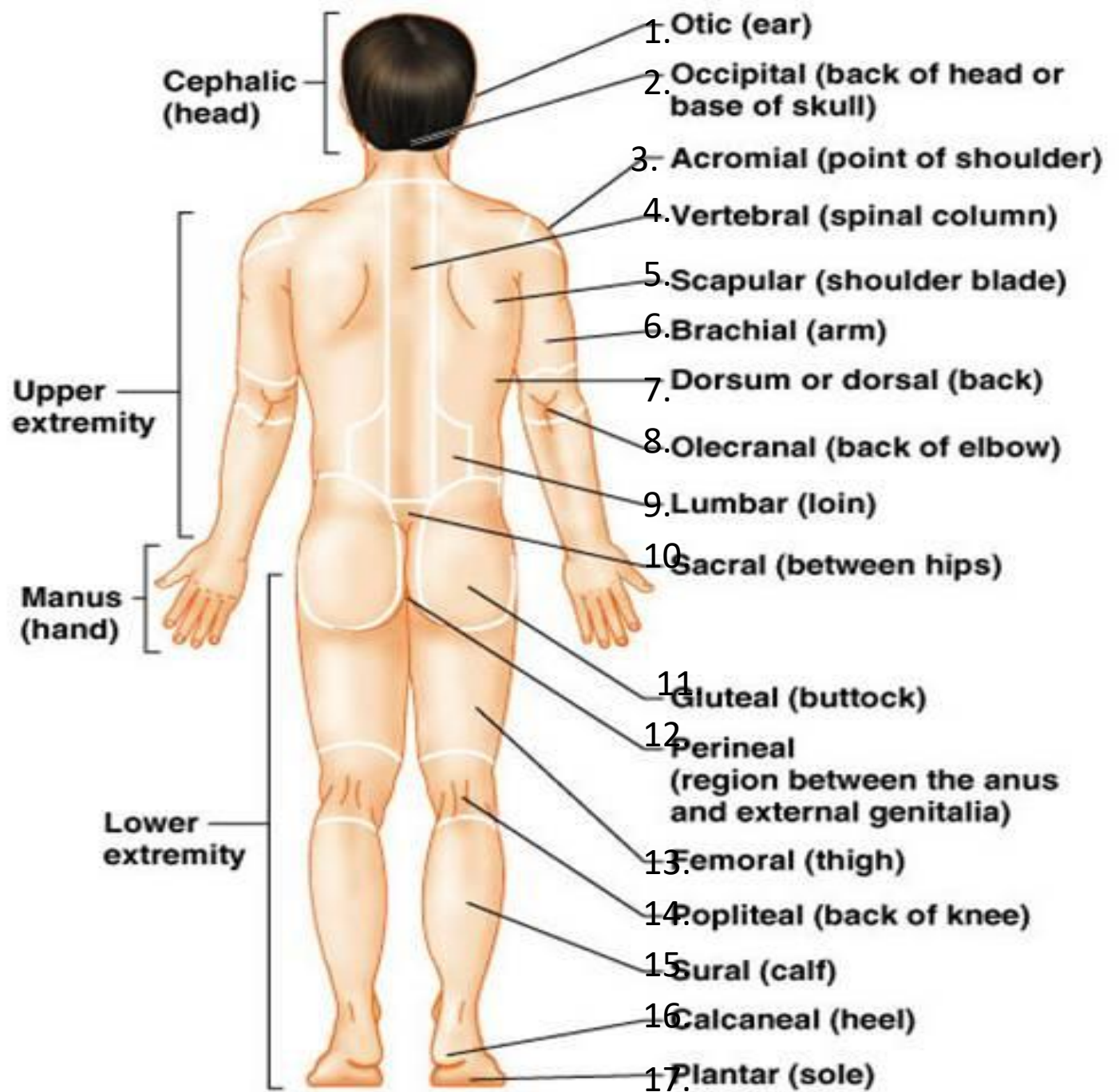
(a) Anterior

Regions



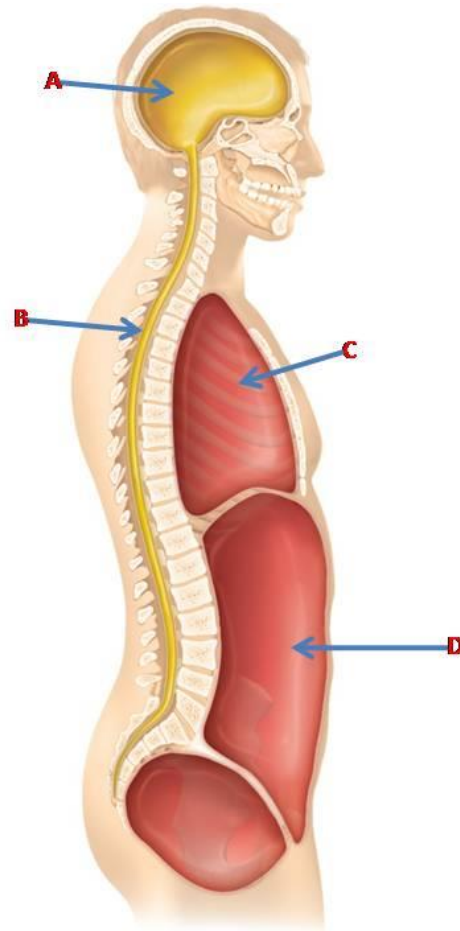
(b) Posterior

S



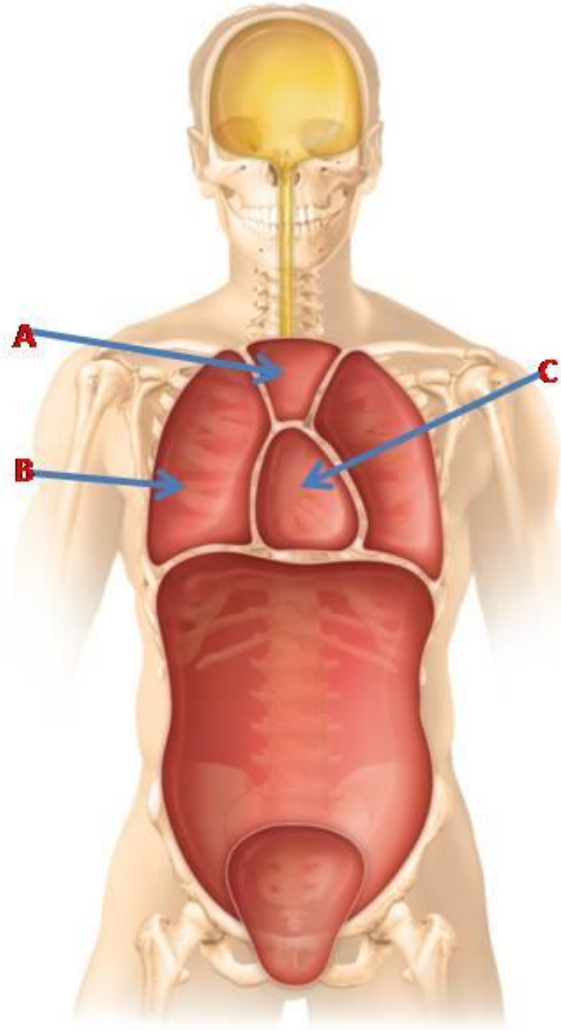
(b) Posterior

Cavities



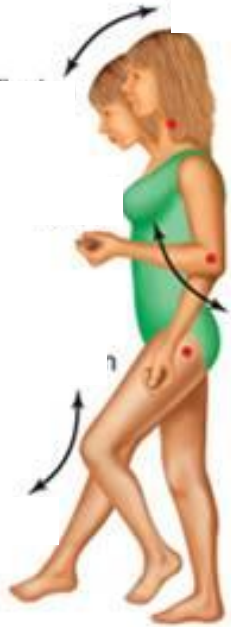Cavities

-

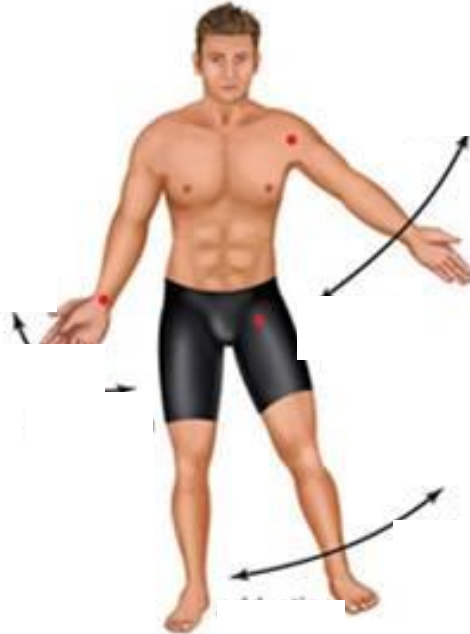

Movements

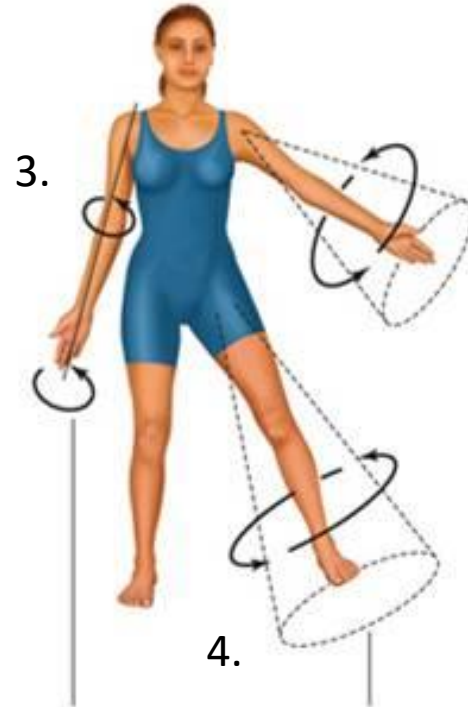
Copyright © The McGraw-Hill Companies, Inc. Permission required for reproduction or display.



1.



2.



4.

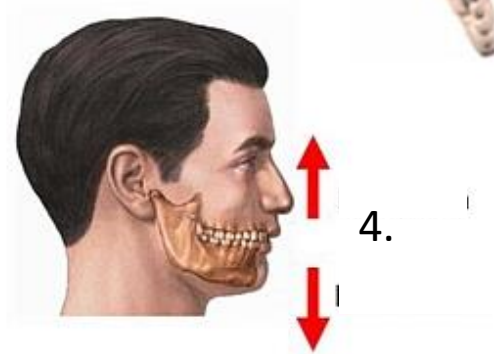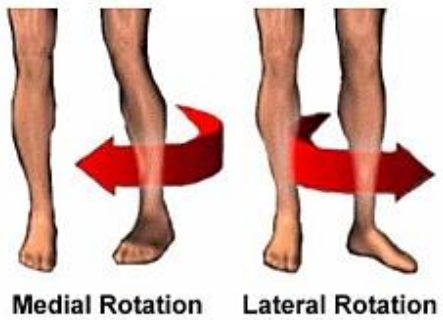
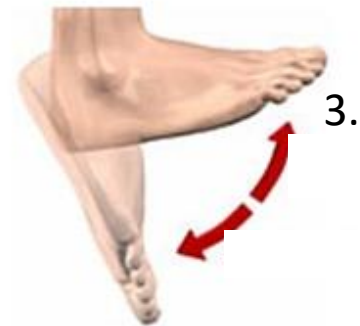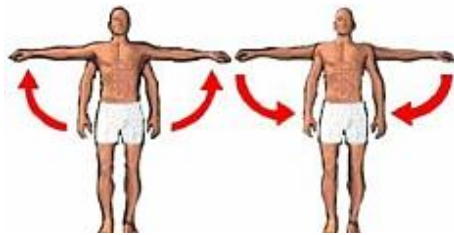
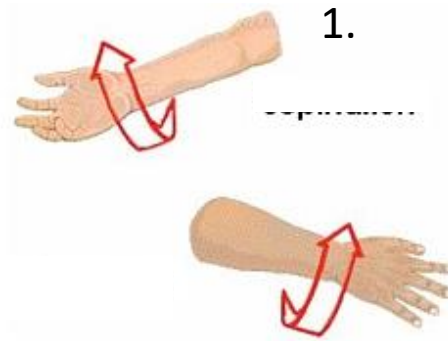
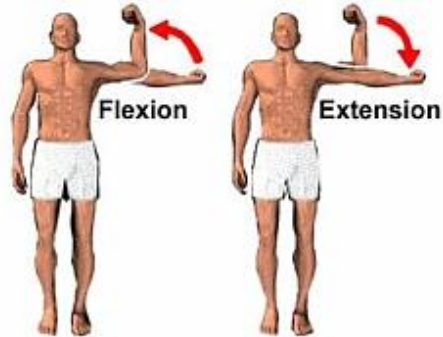


6.



5.

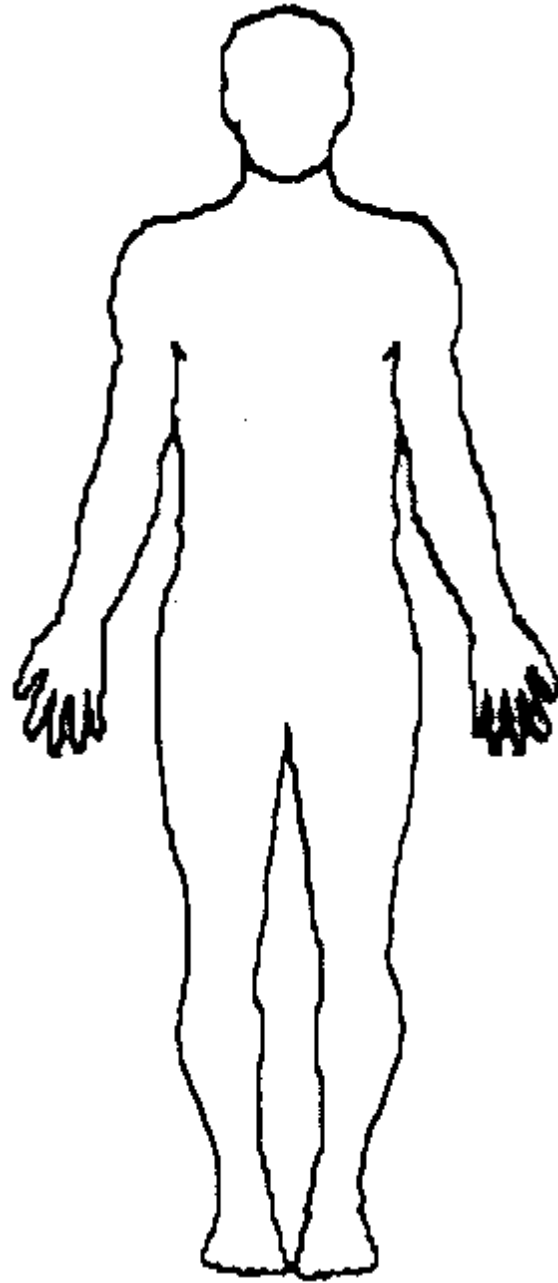
Movements



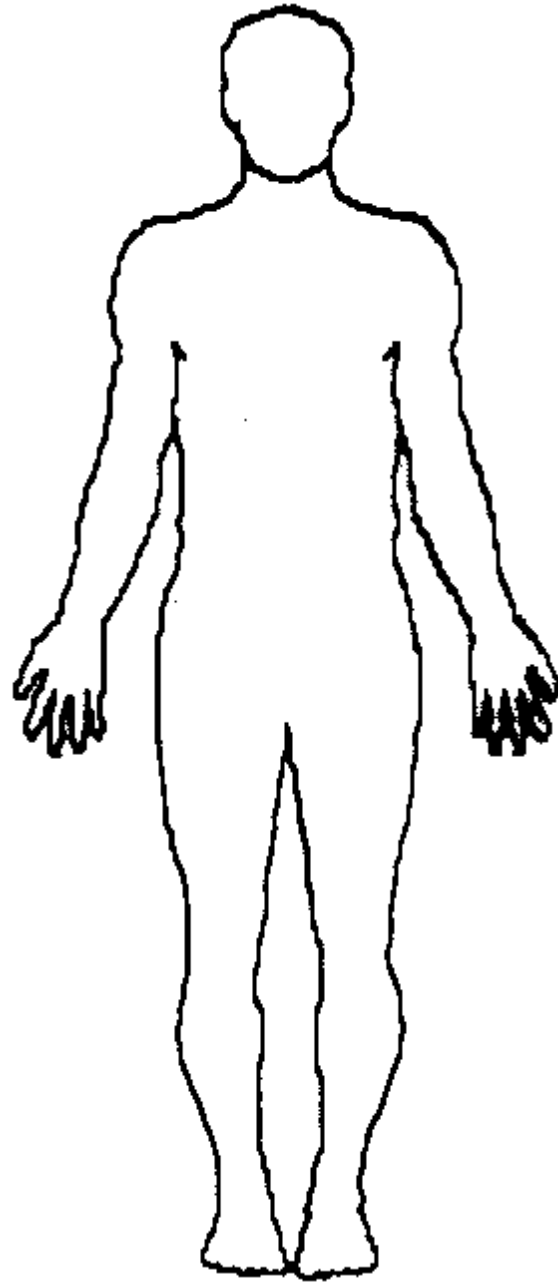
Directions

- The Shoulder is _____ to the wrist.
- The knee is _____ to the ankle.
- The ankle is _____ to the hip.

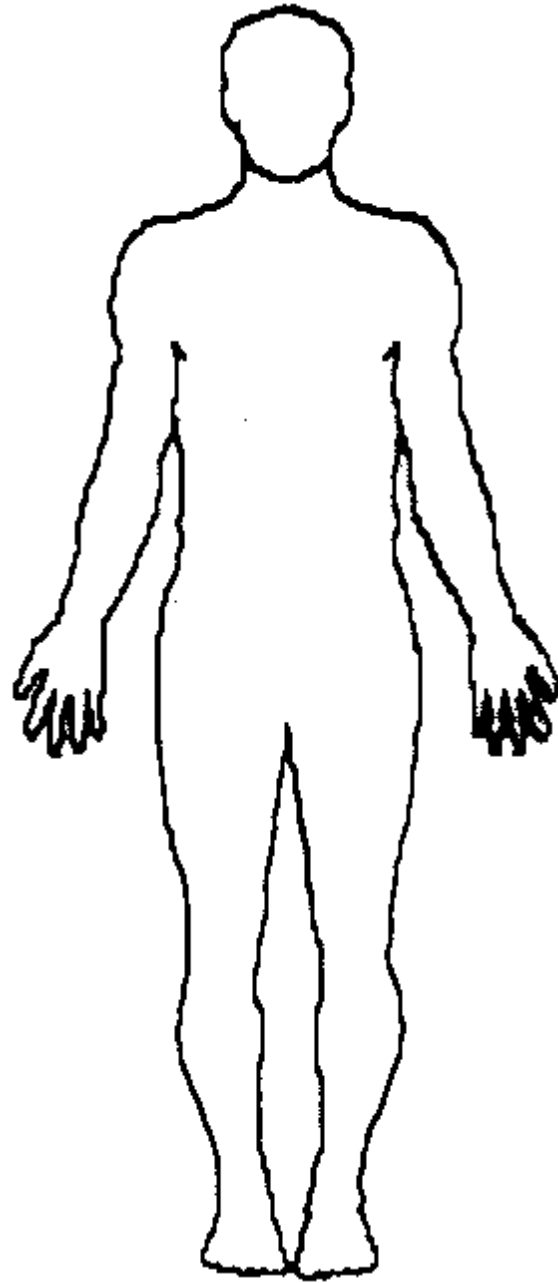
Directions



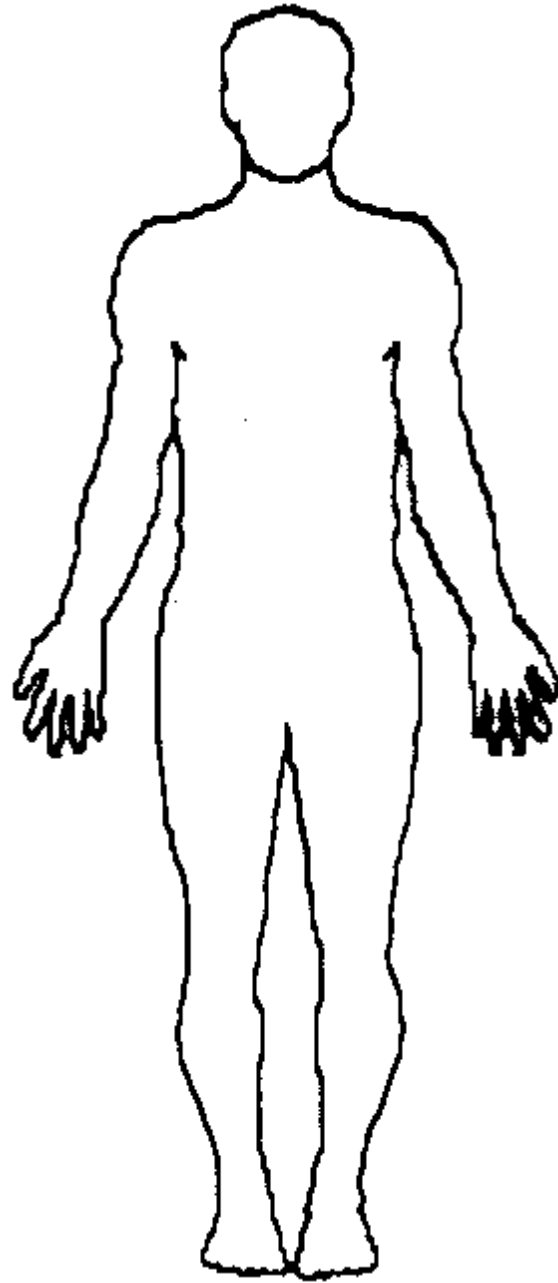
Directions



Directions



Directions



Directions

